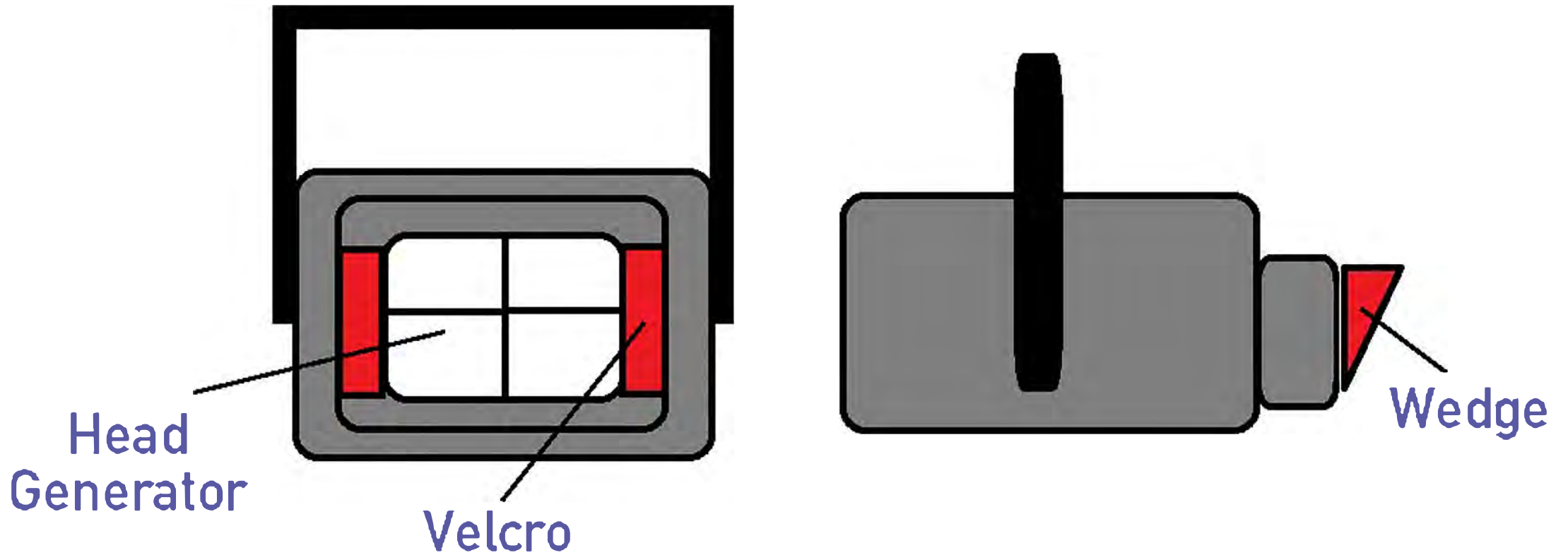



User Instructions Aluminium Wedge



How to perform a good lateral radiographic view of the thoracolumbal spine of the adult horse

1. Use a powerful machine:
 - at least 60 to 80 KW
 - preferably use a DR system (for more sensitivity)
 - 105 to 120 kv and 90 to 180 mAs depending on the size of the horse
2. Have a legal and very effective radiation protection plan
3. Sedate the horse and place him perfectly square

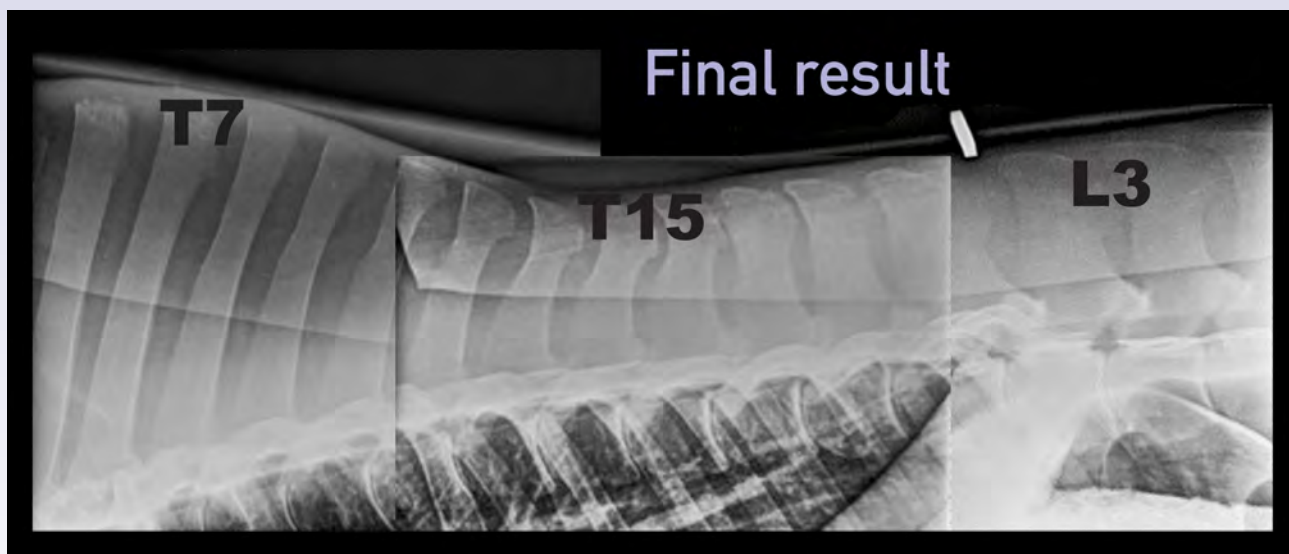
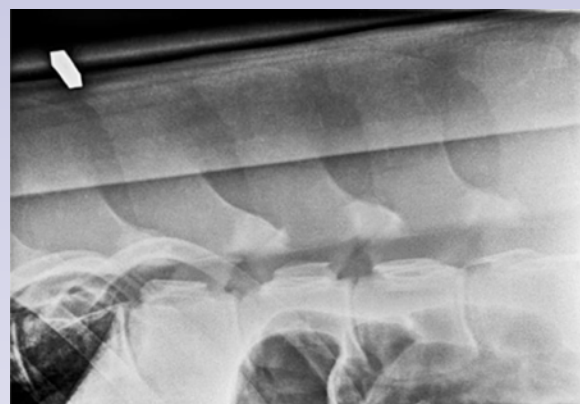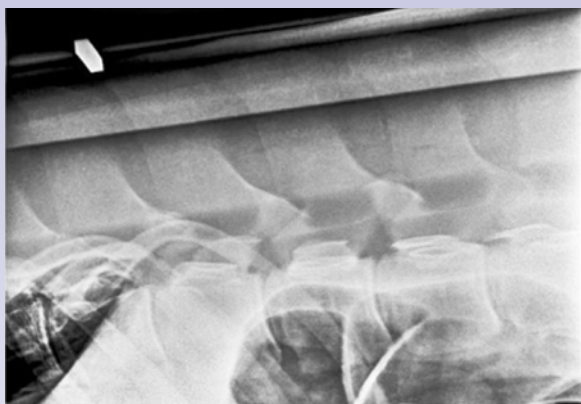
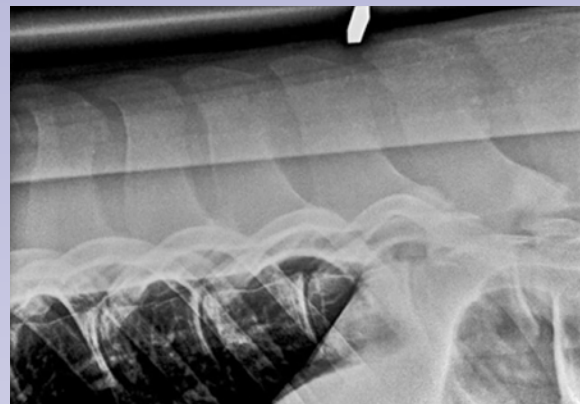
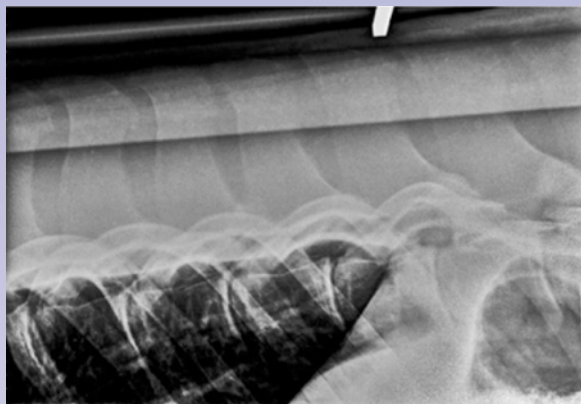


4. Use a good grid (ratio 8 or 10) with a large cassette (30 x 40 cm)
5. Use and properly place the Denoix Wedge
 - place 2 lead markers on the back
 - The Denoix Wedge is delivered with a contra-weight for ideal positioning and ease-of-use



Home-made aluminium wedge vs. Denoix Wedge

(same 580 kg horse, 115 kv, 1.1 m, 180 mAs)



Courtesy of Dr. Jean-Marc Betsch, Clinique Vétérinaire Equine de Méheudin



www.podoblock.com